

Third-Degree Heart Block in Thalassemia major: A Case Report

Ali R. Maleki* ¹; Bagher Nikyar ², MD, and Seyed M. Hosseini ³, MD

1. Student Research Committee, Golestan University of Medical Sciences, Gorgan, Iran
2. Department of Pediatrics, Golestan University of Medical Sciences, Gorgan, Iran
3. Department of Physiology, Golestan University of Medical Sciences, Gorgan, Iran

Received: Dec 13, 2010; Final Revision: Aug 08, 2011; Accepted: Oct 07, 2011

Abstract

Background: First and second-degree heart blocks are partly common rhythm disorders in thalassemic patients but complete heart block is a very rare complication of iron overload cardiomyopathy.

Case Presentation: This 15-year-old boy, a known case of major β -thalassemia was admitted to our emergency unit with dyspnea and cough because of decompensated heart failure. The electrocardiogram showed complete heart block with junctional escape rhythm. Interestingly, his previous electrocardiogram taken 2 months earlier, had some PVC and second degree, Mobitz type 1 (Wenckebach) heart block. After improvement of dyspnea and control of blood pressure in normal range, the patient was referred to ER. A dual-chamber permanent pacemaker was implanted and his symptoms improved, but he died 24 days after discharge from hospital.

Conclusion: We present a rare case of complete heart block after a second-degree (Mobitz 1) heart block that was due to severe iron overload cardiomyopathy.

Iranian Journal of Pediatrics, Volume 22 (Number 2), June 2012, Pages: 260-264

Key Words: β -Thalassemia, Arrhythmia, Iron overload; Cardiomyopathy

Introduction

Thalassemia major is the most common monogenic disorder causing a complete absence of β -globin gene production [1]. There is some inevitably pursuant complication in thalassemia major patient from iron overload in various organs such as heart, liver and pancreas. Cardiac iron overload or iron overload cardiomyopathy (IOC) is the most serious condition [2]. Congestive heart failure and cardiac arrhythmias are the most common lethal complications in these patients. First and second-degree heart blocks are partly

common rhythm disorders in thalassemic patients but complete heart block is an absolutely rare complication [3]. We present here the case of a young boy with second and third degree heart block and severe congestive heart failure due to IOC.

Case Presentation

This 15-year-old boy was admitted to our emergency unit with complaints of abdominal and

* Corresponding Author;

Address: Deputy for Research and Technology, Student Research Committee, Golestan University of Medical Sciences, Gorgan, Iran.

E-mail: ali.r.maleki@gmail.com

© 2012 by Pediatrics Center of Excellence, Children's Medical Center, Tehran University of Medical Sciences, All rights reserved.

back pain, dyspnea and cough for 2-3 months prior to presentation. He was a known case of major β -thalassemia who had been hospitalized twice for the same complaints during the last two months. The diagnosis was made by the age of 8 months [hemoglobin (Hgb) A 87.5%, Hgb A₂ 2.2%, Hgb F 10.3%] and from then on, he underwent intermittent whole blood transfusions every 25 days (390 milliliter at last time). Subcutaneous deferoxamine injection started at age 5, using portable pump. He has had good compliance for blood transfusion and chelation therapy.

His past medical history included splenectomy at age 6. Physical examination revealed a lethargic and febrile boy with a typical thalassemic feature, mild jaundice and respiratory distress at rest. His pulse rate was 42/min with blood pressure 108/72 mmHg and 93% arterial O₂ saturation (with pulse-oximetry). He had periorbital and lower limb edema, pale conjunctivae and icteric sclera. Examination of cardiovascular system revealed muffled cardiac sounds with no detectable murmur. His right jugular vein pulsation point was raised and prominent. Lung auscultation was clean but there was decreased breathing sound in both lungs that was more severe in the bases of the lungs. Examination of the abdomen revealed a huge tender hepatomegaly, distension and dullness in

percussion. A 15 cm midline scar was also seen in abdomen. Laboratory findings: hemoglobin 11.4 mg/dl, mean cell volume 98.32 fL, white cells $11.6 \times 10^9/L$, platelets $161 \times 10^6/L$, potassium 5 mg/dl, urea 13 mg/dl, creatinine 0.6 mg/dl, blood glucose 74 mg/dl, serum iron 219 $\mu\text{g/dl}$, ferritin 7600 ng/ml, total iron binding capacity (TIBC) 250mg/dl, serum glutamic oxaloacetic transaminase (SGOT) 84 IU/L, serum glutamic pyruvic transaminase (SGPT) 54 IU/L, C-reactive protein (qualitative) negative and calcium 8.6 mg/dl. Blood culture was negative for bacterial aerobic and anaerobic growth.

Chest x-ray showed increased cardio-thoracic ratio and some areas of consolidation in both lungs (Fig. 1). Also bilateral pleural effusion was detected by chest ultrasonography. A trans-thoracic echocardiogram revealed mild mitral regurgitation and moderate tricuspid regurgitation and a diffused dilation of all cardiac chambers. Right and left ventricle had severe systolic dysfunction. Also massive pericardial effusion was detected. Unfortunately, cardiac MRI was not performed.

The electrocardiogram showed complete heart block with junctional escape rhythm (Fig. 2). Interestingly, his previous electrocardiogram taken 2 months earlier had some premature ventricular contractions (PVC) and second degree

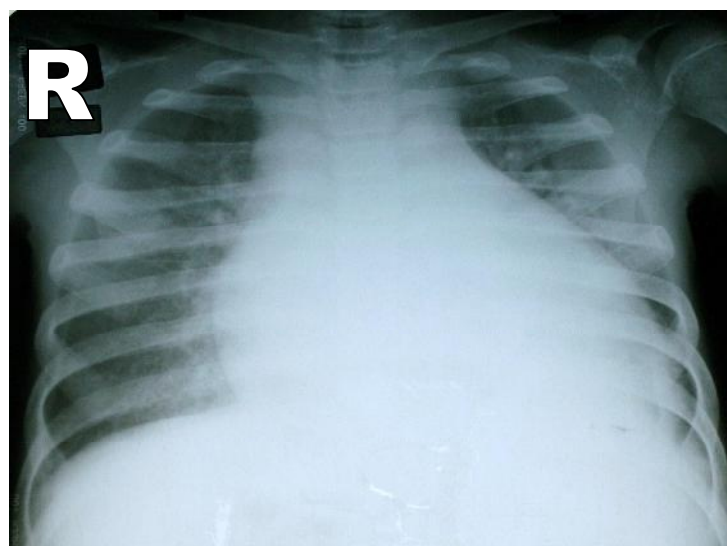


Fig. 1: Patient's chest x-ray on admission showed increased cardio-thoracic ratio and some areas of consolidation in both lungs

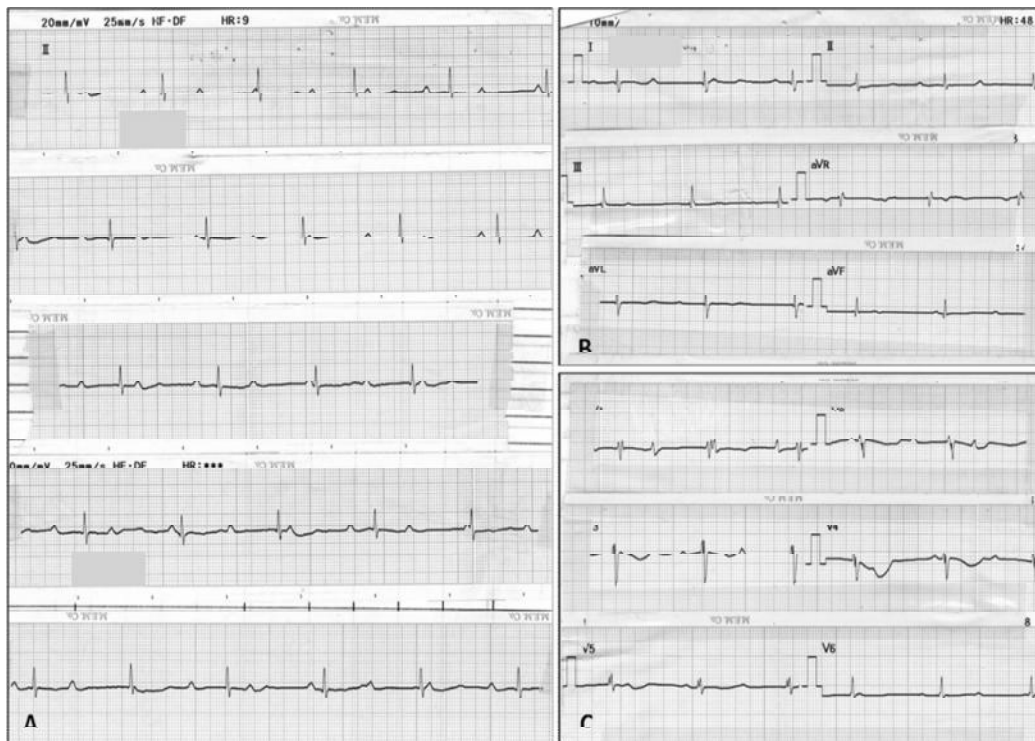


Fig. 2: Electrocardiogram of patient at the last admission before pacemaker installation revealed complete atrioventricular block (third degree) with atrioventricular dissociation in long lead II (A), limb leads (B) and precordial leads (C)

Mobitz type 1 (Wenckebach) heart block taken 2 months earlier had some PVC and second degree Mobitz type 1 (Wenckebach) heart block (Fig. 3).

The patient was briefly managed with Furosemide, Captopril, Digoxin, Aldacton and Ceftriaxon. He had a fixed bradycardia (heart rate less than 45) that did not change after Dopamin infusion (15 drops per minute of 50% solution). After improvement of dyspnea and tachypnea and control of blood pressure in normal range, patient was referred for permanent pacemaker implantation. A dual-chamber permanent pacemaker (ST. JUDE MEDICAL) was implanted and his symptoms improved, but suddenly, he died 24 days later due to ventricular tachycardia.

Discussion

Cardiac complications of thalassemia major were first described by Engle and colleagues prior to introduction of chelation therapy^[4]. Engle

described the increase in heart size with first degree heart block after 10 years of age in one third of thalassemic patients. Generally, once heart failure occurs the survival time is less than three months if left untreated^[5]. Currently, cardiomyopathy is the leading cause of morbidity and mortality in 63.6% to 71% of patients^[1]. Similar to mechanical dysfunction, electrophysiological dysfunction depends on the stage of disease^[1]. Bradycardia, ST segment and T wave changes, infrequent premature atrial or ventricular contractions and first-degree atrioventricular block are the most common findings in early stage^[6,9], that may progress to frequent premature atrial or ventricular contractions, short runs of supraventricular tachycardia and second-degree or third-degree heart block in the late stage^[4,7]. Among these late electrocardiogram changes, frequent premature ventricular contraction is most commonly found^[7]. Non-transferrin-bound iron (NTBI) has been shown to be the main cause of cytotoxicity^[1]. Recently, the L-type calcium channel was proposed as the pathway of intracellular NTBI uptake in cardiomyocytes and

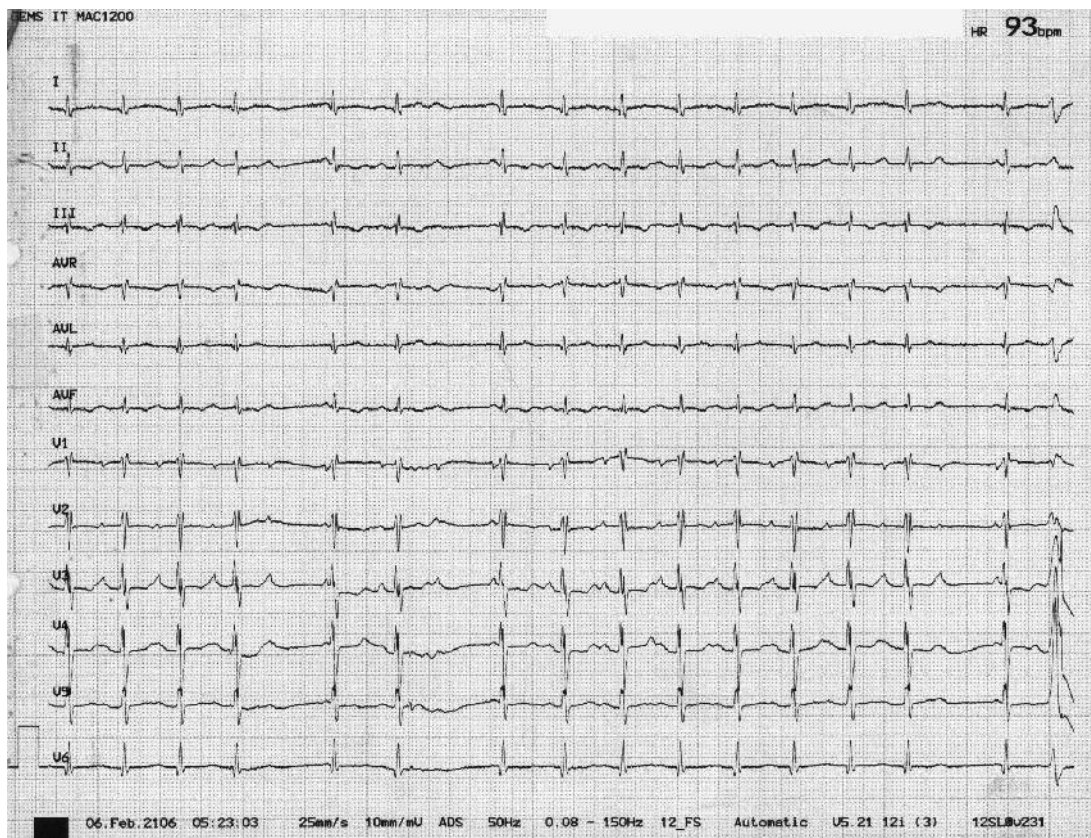

Fig 3: The 12 leads electrocardiogram from the previous admission of the patient revealed second degree Mobitz type 1 (Wenckebach) heart block.

calcium channel blockers have shown to be useful in preventing NTBI from entering cardiomyocytes via these channels [8].

We could find only a case report of third-degree heart block in thalassemia major by Küçükosmanoğlu et al when searched PubMed and other electronic databases. Küçükosmanoğlu reported a case of complete heart block with serious congestive heart failure in whom management by pacemaker had no clinical improvement and the patient died in second month of hospitalization [3]. We presented here a thalassemia major patient with complete heart block. This arrhythmia was developed after a second-degree heart block and transient premature ventricular contractures from few months earlier. Similarly our patient died few weeks after pacemaker implantation.

These complications are reversible in some patients by early detection of iron deposition and then intensive iron chelation therapy [5]. The T2-

star magnetic resonance has been recently developed to assess cardiac iron status accurately and detect an early global ventricular dysfunction [9]. In comparison, conventional standard echocardiography usually demonstrates positive findings at the late stage [10]. In our case MRI was not performed due to poor socioeconomic state of the family and late patient referral.

Patient's hemodynamic state was not stabilized using diuretics and digitalis because of low heart rate. So we administered cardiac dose of dopamine to increase cardiac output. Long term administration of third generation beta-blockers (e.g. Carvedilol) has been demonstrated to favorably affect survival in adult patients with severe chronic heart failure [11]. A recent study showed patients with thalassemia and dilated cardiomyopathy have poor tolerance to increasing Carvedilol dosage and develop decreased systolic blood pressure during advancement of the drug dosage [12]. Otherwise, many studies showed

reversibility of iron induced cardiomyopathy after treatment by chelation therapy in thalassemia major, but it is not universally accepted due to the high mortality of patients presenting with advanced cardiac failure despite chelation treatment [5].

Conclusion

Atrioventricular blocks, especially complete heart block rarely occur in end-stage IOC. When these abnormalities developed, prognosis is very poor. Early detection of iron overload in asymptomatic patients is the goal of clinical management. Intensive iron chelation therapy is the best way of preventing iron overload. We present a rare case of complete heart block which developed after a second-degree (Mobitz 1) heart block due to severe IOC.

References

1. Lekawanvijit S, Chattipakorn N. Iron overload thalassaemic cardiomyopathy: iron status assessment and mechanisms of mechanical and electrical disturbance due to iron toxicity. *Can J Cardiol* 2009;25(4):213-8.
2. Borgna-Pignatti C, Rugolotto S, De Stefano P, et al. Survival and disease complications in thalassemia major. *Ann NY Acad Sci* 1998;850:227-31.
3. Küçükosmanoğlu O, Ozbarlas N, Saşmaz I. Complete heart block in thalassemia major: a case report. *Turk J Pediatr* 2002;44(3):261-2.
4. Engle MA, Erlandson M, Smith CH. Late cardiac complications of chronic, severe, refractory anemia with hemochromatosis. *Circulation* 1964;30:698-705.
5. Cohen AR, Galanello R, Pennell DJ, et al. Thalassemia. *Hematology Am Soc Hematol Educ Program*. 2004; Pp: 14-34.
6. Veglio F, Melchio R, Rabbia F, et al. Blood pressure and heart rate in young thalassemia major patients. *Am J Hypertens* 1998;11(5):539-47.
7. Kremastinos DT, Tsetsos GA, Tsiapras DP, et al. Heart failure in beta thalassemia: A 5-year follow-up study. *Am J Med* 2001;111(5):349-54.
8. Oudit GY, Sun H, Trivieri MG, et al. L-type Ca²⁺ channels provide a major pathway for iron entry into cardiomyocytes in iron-overload cardiomyopathy. *Nat Med* 2003;9(9):1187-94.
9. Anderson LJ, Holden S, Davis B, et al. Cardiovascular T2-star (T2*) magnetic resonance for the early diagnosis of myocardial iron overload. *Eur Heart J* 2001;22(23):2171-9.
10. Hoffbrand AV. Diagnosing myocardial iron overload. *Eur Heart J* 2001;22(23):2140-1.
11. Prabhu SD, Chandrasekar B, Murray DR, Freeman GL. β -adrenergic blockade in developing heart failure. Effects on myocardial inflammatory cytokines, nitric oxide, and remodeling. *Circulation* 2000;101(17):2103-9.
12. Ajami GH, Amoozgar H, Borzouee M, et al. Efficacy of Carvedilol in patients with dilated cardiomyopathy due to beta-thalassemia major; a double-blind randomized controlled trial. *Iran J Pediatr* 2010;20(3):277-83.