

Study of Foreign-Body Extraction from the Upper Third of the Esophagus in Children

Wen-Kui Bao, MD

Department of Anesthesiology, Affiliated Hospital of Inner Mongolia University for the Nationalities, China

Received: Aug 10, 2013; Accepted: Dec 16, 2013; First Online Available: Feb 10, 2014

Abstract

Background: Throat-operating forceps are an auxiliary tool used for tracheal intubation during general anesthesia as well as for artificial respiration and during airway emergency when tracheal intubation is necessary. These forceps are a commonly used tool particularly for introducing the distal end of the endotracheal catheter into the airway at the epiglottis during difficult airway intubation and nasotracheal intubation. Throat-operating forceps have a required radian for operation at the intraoral epiglottis and have different types (large, medium, and small) that are suitable for patients of different ages. These tools have flexible forceps clamps and target-like, smooth distal ends that do not injure mucous membranes. Given these advantages, throat-operating forceps are used for pediatric endoesophageal foreign-body removal.

Case Presentation: Pediatric patients were anesthetized using different methods according to their age. A total of 15 patients five years to nine years of age were recruited. Foreign bodies were successfully removed without any complications.

Conclusion: Tracheal intubation forceps successfully removes esophageal foreign bodies in children because of the distinct shape of the forceps. The method is simple, feasible, and safe.

Iranian Journal of Pediatrics, Volume 24 (Number 2), April 2014, Pages: 214-218

Key Words: Foreign Body; Esophagus; Throat Operating Forceps

Introduction

Childhood esophageal obstruction caused by dry, salty mustard pieces frequently occur because of eating habits. In April 1996, we successfully treated a patient with such a case in the Affiliated Hospital of Inner Mongolia University for the Nationalities, wherein one or two patients with similar conditions are annually admitted for treatment. Throat-operating forceps, which are normally used as a special instrument for anesthesia, successfully addressed the practical clinical problem during treatment. The use of throat-operating forceps in the aforementioned

case expanded the application of anesthesiology and revealed another function of the tool. The curve of the Boedeker intubation forceps allows both the tip of the forceps and the glottic opening to be simultaneously visible in the field of view during videolaryngoscopy. Thus, the ease of glottic foreign-body removal is improved^[1]. Furthermore, the method expands the field of modern anesthesiology, promotes the use of clinical anesthesia, and emphasizes the importance of general practitioners. In this study, we reviewed, summarized, and explored the use of throat-operating forceps for esophageal foreign-body removal based on successful removal in >10 cases.

* Corresponding Author;

Address: Department of Anesthesiology, Inner Mongolia University for the Nationalities, Tongliao 028000, Inner Mongolia Autonomous Region, China

E-mail: wkdoccn@163.com

© 2014 by Pediatrics Center of Excellence, Children's Medical Center, Tehran University of Medical Sciences, All rights reserved.

Case Presentation

General data

From April 1996 to June 2006, we successfully rescued 15 pediatric patients (nine males and six females), with ages ranging from five years to nine years. In all cases, the foreign bodies were dry, salty mustard pieces based on the definite description of the patients' parents. The longest obstruction time was 3 days, and the shortest time was half a day. Upper gastrointestinal barium radiography clearly located the foreign bodies at the first narrow site of the esophagus. Seven patients who had the obstruction for more than 24 hours presented with varying degrees of dehydration and depression. The most severe patient did not eat or drink for 3 days and had been brought to several hospitals and related divisions before receiving treatment at the Affiliated Hospital of Inner Mongolia University for the Nationalities. He presented with lethargy, dyspnea, hoarseness, enophthalmos, dull facial expressions, and lack of strength to cry. Based on upper gastrointestinal barium radiography, the foreign body was located at the first narrow site of the esophagus. Moreover, the trachea was compressed and narrowed, and barium failed to pass around the foreign body. Out of the 15 patients, 11 received general anesthesia for foreign-body removal, and 4 (with ages ranging from seven years to nine years) received topical anesthesia. This study was conducted in accordance with the declaration of Helsinki and with the approval from the Ethics Committee of Affiliated Hospital of Inner Mongolia University for the Nationalities. Written informed consent was obtained from all participants' guardians.

Treatment methods under general anesthesia

The venous channel was opened after the patient was transferred to the operating room. Lactated Ringer's solution and/or 10% glucose injection was infused as a body fluid and energy supplement. Intravenous anesthesia was performed to minimize irritability during the recovery period. The patient was placed in a supine position on the operating table. Patients with severe tracheal compression exhibited resistance against oxygen inhalation through a veil and increased air pressure. After several minutes, 1.5 mg/kg to 2.5 mg/kg propofol injection (Xi'an

Libang Pharmaceutical Co., Ltd., China) was intravenously infused, with the dose adjusted according to patient constitution. Suxamethonium (1 mg/kg) was also administered. When the diameter of the foreign body was small and the patient did not show severe tracheal compression, a muscle relaxant was not used. After sufficient oxygen inhalation, the patient was placed in a head-back to enable orotracheal intubation under direct vision. His chin was raised with the physician's right hand, and his lips were parted. A laryngoscope was held with the physician's left hand, and a laryngoscopic lens was inserted along the center or at a right angle to the mouth. The lens was moved forward along the midline, and the epiglottis was observed. When the tip of the lens reached the root of the epiglottis, the laryngoscope was raised to reveal the glottis. After the lens was placed intraorally, the thumb and forefinger of the physician's left hand held the laryngoscope handle, whereas the middle and ring fingers held the lower chin of the patient to align the lens with the chin and thus allow full glottal exposure by dragging the chin forward. Otherwise, if the laryngoscope was used in a manner similar to that for adult patients, the laryngoscope would have probably slipped out of the patient's mouth when raised and injure the laryngeal and oral cavities. The upper end of the esophagus posterior to the glottis was observable. Tracheal intubating forceps (Tumed Surgical Instruments & Hospital Supplies GmbH, Germany) were gently inserted into the pharynx and esophagus with the right hand. When the forceps made contact with the foreign body, the jaws of the forceps were extended gently and sufficiently and then moved forward until the foreign body could be held (Figs 1 and 2). The forceps were gently withdrawn after the foreign body was clamped with appropriate strength. The foreign body was then removed.

Treatment method under topical anesthesia

After the patient's mouth was opened, 2% lidocaine (Zhengzhou Cheuk-Fung Pharmaceutical Co., Ltd., China) was sprayed toward the pharynx using a laryngeal spray for sufficient anesthesia. The patient was placed in a supine position on the operating table. The method used for foreign-body removal was the same as that applied under general anesthesia. Treatment under topical

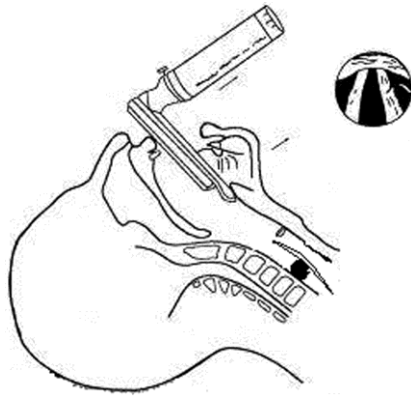


Fig. 1: The schematic diagram of intubation

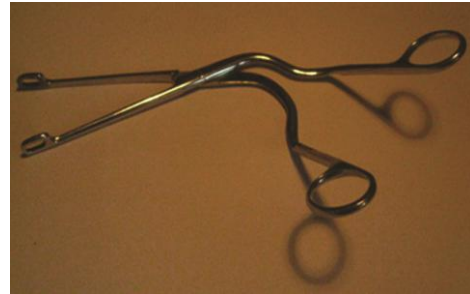

Fig. 2: Throat operating forceps

anesthesia is suitable for relatively old and cooperative pediatric patients. Moreover, the foreign body should be located at the upper part of the narrow site of the esophagus and could be partially seen using laryngoscopy. For anxious patients, an appropriate volume of a sedative could be given.

The removed foreign bodies were all integral, with sizes ranging from 1.5 cm × 2.0 cm to 2.5 cm × 3.0 cm. For the general anesthesia patients, veil air-pressure oxygen was immediately provided. A portion of the obstructed airway was unobstructed and nonresistant. The patients' vital signs were stable. Esophageal hemorrhage and stomach content outflow were observed. All patients recovered from unconsciousness approximately 20 min to 30 min after anesthesia administration. The patients immediately breathed smoothly, swallowed normally, and required eating and drinking. The patients drank an appropriate volume of drinkable sugar or clear water and were observed for 24 h while receiving infusion. The patients were discharged from the hospital when the absence of abnormalities was confirmed based on body fluid and electrolyte examinations. Long-term observation was not required for patients with mild conditions or those receiving local anesthesia.

Discussion

Esophageal foreign-body obstruction frequently occurs in children^[2] particularly at the age of 2 years to 5 years^[3]. Most patients manifest with

dysphagia, vomiting, and sialorrhea^[4]. Timely treatment is necessary for this condition; untimely treatment could result in serious consequences^[5]. The properties and size of the foreign body also affect prognosis^[6], accidental swallowing of foreign bodies has also been reported in adults, and the foreign body is observable in most cases^[7]. For adults, the foreign bodies can also be removed using intubation^[8]. However, treatment with glucagon has no effect^[9]. Some patients may suffer from esophageal perforation because of treatment delay^[10]. The currently used examination methods for esophageal foreign-body obstruction include rapid esophagoscopy and three-dimensional reconstruction^[11,12]. In this study, we successfully treated 15 pediatric patients using throat-operating forceps. The method successfully avoided complex clinical diagnosis and treatment procedures and achieved a direct and rapid effect. In addition, the mean foreign-body removal time was 45 s^[13]. This procedure effectively solves a practical clinical problem without producing side effects or complications. Thus, satisfactory results are achieved. For patients with symptoms but without a history of mistaken swallowing, computed tomography, which has a negative predictive value of approximately 100%, can be used for exclusive diagnosis^[14]. In this study, all 15 patients suffered from foreign-body obstruction at the first narrow site of the esophagus and were all successfully treated using throat-operating forceps. Therefore, this tool is suitable for the removal of blunt foreign bodies from the first narrow site or upper part of the esophagus. For foreign bodies located at the distal end, other methods should be used^[15]. The use of a magnet can be combined with the forceps if the foreign

body is a common coin^[16]. Moreover, a U-shaped tube can be used for a ring-shaped foreign body^[17]. Other common foreign bodies include fish bones^[7] and bristles^[18]. In a US retrospective study that included 101 children who swallowed coins, only 56 children had the esophageal coins removed using forceps, whereas forceps and a Foley catheter were used for the remaining cases^[19]. However, throat-operating forceps cannot be used on prismatic foreign bodies or those that have embedded in the esophageal wall. This problem may be solved by further reconstructing the configuration of throat-operating forceps, such as by installing a viewable structure at the tip.

This study was conducted on the premise that all of the foreign bodies were isogeneric and located at the first narrow site of the esophagus. Thus, the results cannot prove the suitability of this method for other complex situations. Further equipment reconstruction may solve more complex issues. Numerous difficult issues related to clinical emergencies test the skills of clinical specialists, particularly their comprehensive, three-dimensional thinking and critical problem solving. Under such conditions, specialists should quickly analyze and determine the most suitable existing specialist equipment and techniques to use in order to solve these complicated cases. The specialist with the most suitable skills should also be identified to avoid infringement of medical treatment principles. Problem solving should be based on the responsibility of a specialist to the patient and more importantly on established theories and technical principles as well as on the flexible application of knowledge and skills in a clinical setting. In this study, the interventional therapy used by anesthesiologists was proven to be an effective solution in emergency situations and perfectly illustrates the notion that anesthesia is the integration between science and art.

Several issues should be considered in using throat-operating forceps for treatment of esophageal foreign-body obstruction. First, the foreign body must be blunt, not embedded in the esophageal wall, and is located at the upper part of the esophagus. Second, the operation is best performed under endotracheal intubation to prevent reflux of stomach contents into the trachea after foreign-body removal. Third, the general condition of the pediatric patients should

be comprehensively evaluated, and the necessary adjustments should be made prior to the operation. Fourth, endotracheal tubes, first-aid medicines, and suction equipment should be readily available. Fifth, close cooperation with staff from related departments is necessary. Sixth, the type and size of intubating forceps should be selected based on the actual requirements. In this study, Magill-type forceps were used. Seventh, dental injury and pharyngeal hemorrhage should be avoided when a laryngopharyngoscope is used. Finally, dry mustard pieces absorb water and swell in the esophagus if not removed; thus, longer duration of obstruction results in more severe obstruction and tracheal compression.

Conclusion

Tracheal intubation forceps successfully removes esophageal foreign bodies in children because of the distinct shape of the forceps. The method is simple, feasible, and safe.

Conflict of Interest: None

References

1. Boedeker BH, Bernhagen MA, Miller DJ, et al. Comparison of the Magill forceps and the Boedeker (curved) intubation forceps for removal of a foreign body in a Manikin. *J Clin Anesth* 2012;24(1):25-7.
2. Diniz LO, Towbin AJ. Causes of esophageal food bolus impaction in the pediatric population. *Dig Dis Sci* 2012;57(3):690-3.
3. Celik S, Aydemir B, Tanrıku H, et al. Esophageal foreign bodies in children and adults: 20 years experience. *Ulus Travma Acil Cerrahi Derg* 2013; 19(3):229-34.
4. Rybojad B, Niedzielska G, Niedzielski A, et al. Esophageal foreign bodies in pediatric patients: a thirteen-year retrospective study. *ScientificWorldJournal* 2012;2012:102642.
5. Cole S, Kearns D, Magit A. Chronic esophageal foreign bodies and secondary mediastinitis in children. *Ann Otol Rhinol Laryngol* 2011;120(8):42-5.
6. Sung SH, Jeon SW, Son HS, et al. Factors predictive of risk for complications in patients with oesophageal foreign bodies. *Dig Liver Dis* 2011;43(8):632-5.

7. Ambe P, Weber SA, Schauer M, et al. Swallowed foreign bodies in adults. *Dtsch Arztebl Int* 2012; 109(50):869-75.
8. Fincher RK, Osgard EM. A case of mistaken identity: accidental ingestion of coins causing esophageal impaction in an elderly female. *Med Gen Med* 2003; 5(2):3.
9. Weant KA, Weant MP. Safety and efficacy of glucagon for the relief of acute esophageal food impaction. *Am J Health Syst Pharm* 2012;69(7):573-7.
10. Peng A, Li Y, Xiao Z, et al. Study of clinical treatment of esophageal foreign body-induced esophageal perforation with lethal complications. *Eur Arch Otorhinolaryngol* 2012;269(9):2027-36.
11. Orji FT, Akpeh JO, Okolugbo NE. Management of esophageal foreign bodies: experience in a developing country. *World J Surg* 2012;36(5):1083-8.
12. Chang JM, Yoo YS, Kim DW. Application of three-dimensional reconstruction in esophageal foreign bodies. *Korean J Thorac Cardiovasc Surg* 2011; 44(5):368-72.
13. Janik JE, Janik JS. Magill forceps extraction of upper esophageal coins. *J Pediatr Surg* 2003;38(2):227-9.
14. Loh WS, Eu DK, Loh SR, et al. Efficacy of computed tomographic scans in the evaluation of patients with esophageal foreign bodies. *Ann Otol Rhinol Laryngol* 2012;121(10):678-81.
15. Lando T, Cahill AM, Elden L. Distal airway foreign bodies: Importance of a stepwise approach, knowledge of equipment and utilization of other services' expertise. *Int J Pediatr Otorhinolaryngol* 2011;75(7):968-72.
16. Berthold LD, Moritz JD, Sönksen S, et al. Esophageal foreign bodies: removal of the new euro coins with a magnet tube. *Rofo* 2002;174(9):1096-8.
17. Mirhej MA, Koch J, Stansell J. A novel approach to ring-type foreign body removal: the "U-wire". *Gastrointest Endosc* 1999;49(2):243-5.
18. Harlor EJ, Lindemann TL, Kennedy TL. Outdoor grilling hazard: wire bristle esophageal foreign body -- a report of six cases. *Laryngoscope* 2012;122(10): 2216-8.
19. Bhargava R, Brown L. Esophageal coin removal by emergency physicians: a continuous quality improvement project incorporating rapid sequence intubation. *CJEM* 2011;13(1):28-33.