

Congenital Insensitivity to Pain with Anhidrosis (HSAN Type IV), Extremely Rare Syndrome that Can Be Easily Missed by Bone and Joint Surgeons: A Case Report

Nadeem Ali, MBBS; Sudesh Sharma, MS; Sonali Sharma, MBBS; Younis Kamal, MS, and Sushil Sharma, MS

Department of Orthopedics Postgraduate, Govt. Medical College Jammu

Received: Apr 14, 2011; Final Revision: Mar 25, 2012; Accepted: Apr 08, 2012

Abstract

Background: Congenital insensitivity to pain with anhidrosis is an extremely rare disorder in which injuries can often be missed by patient, parents and even by orthopedic surgeon. Pain and tenderness, on which a trauma team so much depends to make a clinical diagnosis and to decide whether to go for radiological evaluation can be misleading in this rare syndrome. So complete clinical examination still forms the corner stone to avoid misdiagnosis and pick up the rare disorders.

Case Presentation: We present a 5 year old girl child, who was brought to us as a case of one and a half month old neglected trauma left leg and was diagnosed to be suffering from congenital insensitivity to pain with anhidrosis (HSAN Type IV).

Conclusion: Congenital insensitivity to pain with anhidrosis is extremely rare entity, in which patients are subjected to repeated injuries which are often neglected. There is no specific treatment but patient training and parent education are key to avoid further neglect and damage.

Iranian Journal of Pediatrics, Volume 22 (Number 4), December 2012, Pages: 559-563

Key Words: Congenital Insensitivity to Pain with Anhidrosis; Hereditary sensory autonomic neuropathy; Anhidrosis; Osteoacrololysis; Hyperpyrexia

Introduction

Pain is a protective mechanism with great survival value. It is pain which makes patient to seek medical attention. There are different causes of sensation of pain being absent most of which are acquired. Here we present a case of congenital insensitivity to pain with anhidrosis (Hereditary sensory autonomic neuropathy type IV). This is a very rare disorder and as per literature less than sixty cases have been reported and it first described by Swanson in 1963^[1].

Case Presentation

A 5 year old girl of Indo-Aryan origin presented with one and a half month old neglected trauma left leg, managed by a local bone setter (quack). Examination revealed swelling from knee to ankle, 5cm×5cm ulceration over proximal part of shin, purulent discharging sinus and deformity. X-ray revealed non-union with exuberant callus at the fracture site.

At the age of 2 years patient developed ulcers of multiple fingers and toes followed by their self

*** Corresponding Author;**

Address: PG Boys Hostel, Govt. Medical College Jammu, Bakshi Nagar, Jammu, Jammu and Kashmir, Pin 180001, India

E-mail: drnadeem@gmail.com

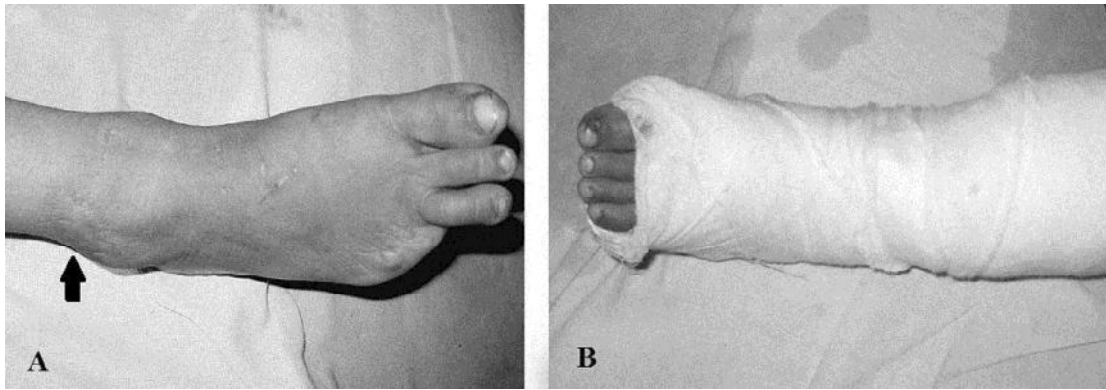


Fig. 1: **A.** Right foot with ankle showing multiple scars and amputated 4th and 5th toes. A big scar (arrow) 4×3cm just above lateral malleolus can also be seen, **B.** Left foot and leg in posterior splint showing absent 5th toe

amputation (Fig. 1, Fig. 2). Finger and toe tips showed multiple healed scars. Radiographs revealed osteoacrololysis (Fig. 3). In the same year, patient had trauma to left thumb which healed with a deformity (Fig. 4). There had been trauma to left forearm in childhood; X-ray revealed healed fracture of shaft of ulna. Parents mentioned all the above traumatic events were not associated with pain.

Around the age of 2 and half years patient developed blisters over right lower extremity,

which healed leaving scar marks (Fig. 1).

There is history of recurrent episodes of high grade fever since childhood. There was one such episode in the hospital lasting 4 days. There is history of lack of sweating since birth. Physical and laboratory tests revealed anhidrosis. Patient feels very uncomfortable during hot weather and comforts herself by taking a cold water bath which gives temporary relief.

She is born of non-consanguineous marriage. Family history was insignificant. Motor and mental

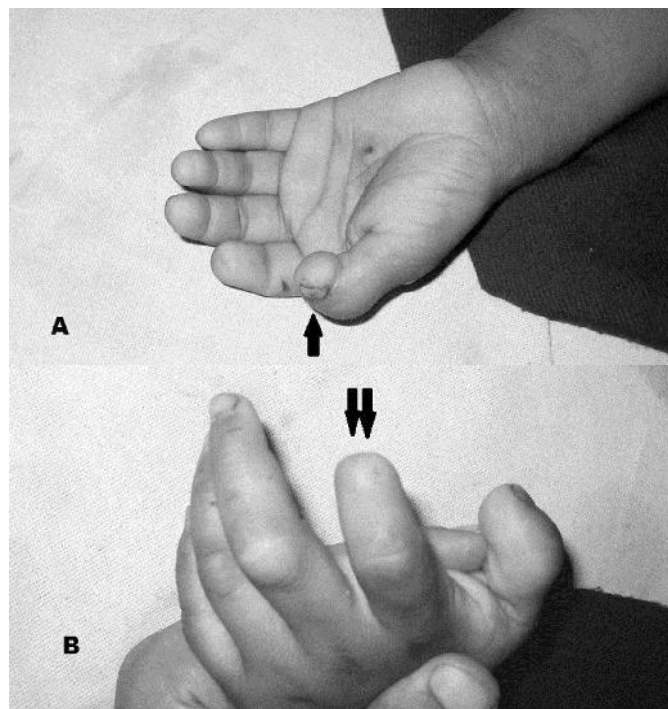


Fig. 2: Photographs of left hand. **A.** Post traumatic deformity of thumb (arrow) and multiple healed scars, **B.** Missing terminal part of index finger (double arrow)

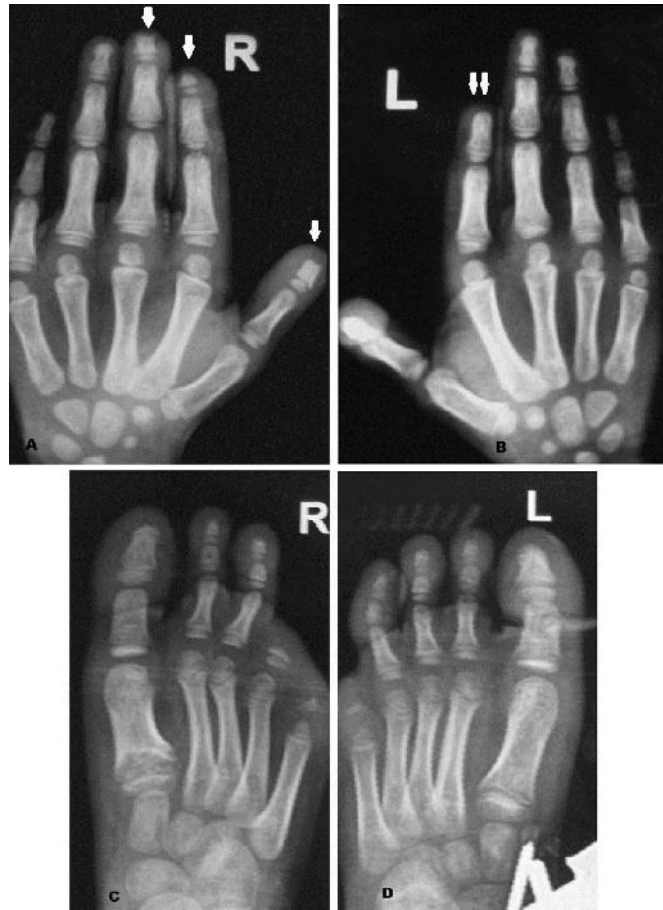


Fig. 3: Radiographs of hands and feet **A.** Right hand showing osteoacrolysis of distal phalanx (arrow) of thumb, index finger and middle finger. **B.** Left hand showing missing terminal phalanx of index finger (double arrow). **C.** Right foot showing absent 4th and 5th toes and osteoacrolysis of terminal phalanx of 3rd toe. **D.** Left foot with missing 5th toe

milestones were delayed. Intelligence is low as compared to other siblings. There is history of repeated respiratory tract infections in childhood.

Neurological examination was normal except

inability to perceive painful stimuli. No pain was perceived even at the time of intravenous and intramuscular injections. Nerve conduction study revealed normal median nerve conduction

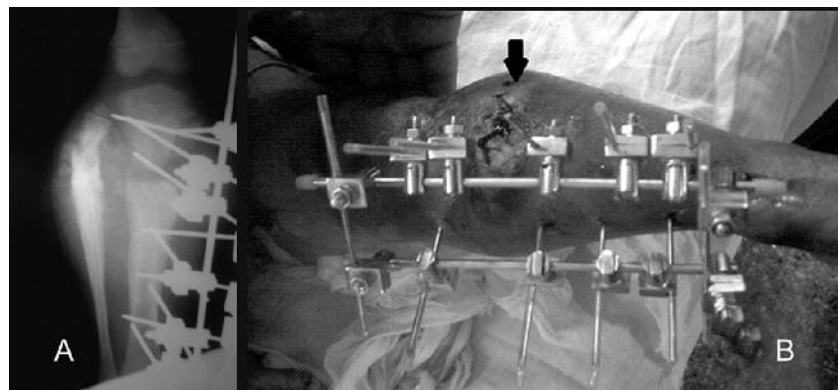


Fig. 4: **A.** Postoperative radiograph showing reduction and stabilization with an external fixator, **B.** External fixation of fracture proximal both bones left leg with a biplane external fixator. Wound (arrow) after excision of the discharging sinus and debridement can also be seen.

velocity. There is history of several episodes of biting of tongue. The patient had normal eruption of teeth but had lost most of them; all the incisors and canines were absent.

CRP was elevated. Culture of pus from discharging sinus cultured *S. aureus*. Serum calcium, serum phosphorus, renal function parameters, thyroid function tests, parathormone levels, serum uric acid were in normal range. Infected non-union was managed by curettage and debridement. Reduction was achieved and fixed using biplanar external fixator (Fig. 4). At 3 months follow up pus discharge had subsided with abundant granulation tissue at wound site. There was callus formation at fracture site and features of union on radiograph.

Discussion

Pain is protective mechanism, which if lost can result in multiple injuries. Most of the time cause is acquired. Occasionally it can be congenital. One such congenital disorder characterized by insensitivity to painful stimulus, anhidrosis and recurrent episodes of hyperpyrexia since birth is known as CIPA (congenital insensitivity to pain with anhidrosis)^[2]. Our case presented with all these features. These patients have been grouped under the broader term HSAN (hereditary sensory autonomic neuropathy) which has 5 types, described by Dyck on the basis of natural history, hereditary transmission, clinical presentation and neuropathological findings^[3]. CIPA has been labelled as HSAN Type IV^[3,4], and is extremely rare disorder with autosomal recessive inheritance^[5]. In our case there was no such family history, so possibility of different mode of transmission may be there. Exact number of cases reported varies, but as per literature of 1998 around thirty or more cases have been reported^[2]. The first clue to diagnosis is recurrent episodes of hyperpyrexia after birth^[6] and in 20% death occurs from hyperpyrexia within 3 years of age^[6].

Pain insensitivity is characterized by biting of tongue, lips, and fingers, painless recurrent fractures and dislocations, blisters, ulcers and

infection of skin, corneal ulcers and opacity. Another feature associated with this disorder is auto amputation with osteoacrolysis of fingers and toes^[4,5] which is also documented with our case. Autonomic abnormalities include inability to sweat in response to elevated temperature or chemical stimuli.

Nerve conduction studies are normal^[2,4] so was in our case. Skin biopsy demonstrates decreased dermal innervations, and sweat glands lack innervations. Nerve biopsy (sural nerve) demonstrates decrease in number of nonmyelinated fibers and decrease in diameter of myelinated fibers^[8]. It requires facility of electron microscope which is not available at our institute.

Multiple joint deformities (Charcot joints) as a consequence of multiple painless intra-articular fractures can occur with increasing age^[4,9]. Severe self-mutilating injuries to tongue, hands, lips, and oral mucosa caused by biting and premature loss of permanent tooth germ are also a feature^[9].

Our case also had history of recurrent respiratory tract infections. Infections may occur secondary to hypogammaglobulinemia, a feature not previously known to be associated with CIPA^[11]. Exact aetiology is not known. It is postulated mutations in nerve tyrosine kinase A/ nerve growth factor (NTrKA/NGF) receptor gene may be responsible. NTrKA-NGF system has a role in development and function of nociceptive reception and thermoregulation via sweating^[5]. Inability to transduce NGF into growing sympathetic and sensory neurons results in apoptosis of this subset of neurons that is NGF dependent^[7].

The orthopedic symptoms lead often to diagnosis and they are an important step to determine the prognosis. The orthopedic and surgical treatment is difficult and must emphasize on the prevention of bone and joint injuries^[12].

Conclusion

There is no specific treatment for this disease. Early diagnosis, patient training and parent education for prevention of trauma and its

immediate management, care of eyes to prevent corneal ulceration, prompt treatment of episodes of hyperpyrexia, application of splints on eruption of sharp permanent teeth form the cornerstone of management of this rare disorder.

Wide surgical debridement with antibiotic therapy for local infections, corrective osteotomies for deformities, shoe raise or epiphysiodesis for shortening may be needed. These patients need regular follow up to come out with the course and other unknown consequences of this rare syndrome.

Acknowledgement

We are thankful to Department of Radiology, Department of Neurology and laboratory staff for various relevant investigations. Written informed consent was obtained from the patient's father for publication of this case report and any accompanying images. A copy of the written consent is available for review by the Editorial board.

Conflict of Interest: None

References

1. Swanson AG. Congenital insensitivity to pain with anhidrosis. A unique syndrome in two male siblings. *Arch Neurol* 1963;8:299-306.
2. Kim JS, Woo YJ, Kim GM, et al. Congenital insensitivity to pain with anhidrosis: a case report. *J Korean Med Sci* 1999;14(4):460-4.
3. Dyck PJ. Neuronal atrophy and degeneration predominantly affecting peripheral sensory and autonomic neurons. In: Dyck PJ, Thomas PK, Griffin JW, Law PA, Peduslo JF, eds. *Peripheral neuropathy*, 3rd edition. Philadelphia, Saunders 1993; Pp: 1065-93.
4. Daneshjou K, Jafarieh H, Raeskarami SR. Congenital Insensitivity to Pain and Anhidrosis (CIPA) Syndrome; A Report of 4 Cases. *Iran J Pediatr* 2012;22(3):412-6.
5. Rosemberg S, Marie SK, Kliemann S. Congenital insensitivity to pain with anhidrosis (hereditary sensory and autonomic neuropathy type IV). *Pediatr Neurol* 1994;11(1):50-6.
6. Gupta B. Congenital insensitivity of pain with anhidrosis; clinical brief. *Indian J Pediatr* 2003; 70(1):109-11.
7. Hu Jun, Zhang Ai-bin, Lin Zhen, Zhou Jiang-nan. Congenital insensitivity to pain with anhidrosis and progressing acro-osteolysis: a case report with 7-year follow-up. *Chin Med J* 2006;119(24):2134-7.
8. Nagasako EM, Oahlander AL, Dworkin RH. Congenital insensitivity to pain: an update. *Pain* 2003;101(3):213-21.
9. Mobini M, Javadzadeh A, Forghanizadeh J. Neuropathic osteoarthropathy in a patient with congenital insensitivity to pain. *Arch Iran Med* 2009;12(6):599-602.
10. Neves BG, Roza RT, Castro GF. Traumatic lesions from congenital insensitivity to pain with anhidrosis in a pediatric patient: dental management. *Dent Traumatol* 2009;25(5):545-9.
11. Kilic SS, Ozturk R, Sarisozen B, et al. Humoral immunodeficiency in congenital insensitivity to pain with anhidrosis. *Neurogenetics* 2008;10(2): 161-5.
12. Bronfen C, Bensahel H, Teule JG. Orthopedic aspects of congenital insensitivity to pain. *Chir Pediatr* 1985;26(3):193-6.